Robert Lopez-Ben, MD
Donald H. Lee, MD
Daniel J. Nicolodi, MD

Index terms:
Tendons, injuries, 437.146, 437.421
Tendons, MR, 437.12141
Tendons, US, 437.1298

Published online before print
10.1148/radiol.2283020833
Radiology 2003; 228:642–646

Abbreviation:
MP = metacarpophalangeal

[1] From the Departments of Radiology (R.L.B.) and Surgery, Division of Orthopaedic Surgery (D.H.L., D.J.N.), University of Alabama School of Medicine and Hospitals, 619 19th St S, JT 360, Birmingham, AL 35249-6830. Received July 24, 2002; revision requested August 27; final revision received November 25; accepted December 19. **Address correspondence to** R.L.B. (e-mail: *rlopez@uabmc.edu*).

Author contributions:
Guarantor of integrity of entire study, R.L.B.; study concepts, R.L.B.; study design, R.L.B., D.H.L., D.J.N.; literature research, R.L.B., D.J.N.; clinical studies, R.L.B., D.H.L., D.J.N.; data acquisition, R.L.B., D.H.L., D.J.N.; data analysis/interpretation, R.L.B., D.H.L.; manuscript preparation, R.L.B., D.H.L., D.J.N.; manuscript definition of intellectual content, R.L.B.; manuscript editing, R.L.B., D.H.L., D.J.N.; manuscript revision/review, R.L.B., D.H.L.; manuscript final version approval, R.L.B., D.H.L., D.J.N.

Boxer Knuckle (Injury of the Extensor Hood with Extensor Tendon Subluxation): Diagnosis with Dynamic US—Report of Three Cases[1]

The use of dynamic ultrasonography (US) in diagnosing traumatic and nontraumatic extensor tendon dislocations in fingers of three subjects is reported. Dynamic US of the clenched fist in two patients with traumatic injury revealed dislocated but grossly intact tendons surrounded by soft-tissue edema; magnetic resonance (MR) imaging in one patient indicated similar findings. Rupture in the sagittal band of the extensor hood mechanism in the two patients was confirmed at surgery. The third subject, an asymptomatic volunteer, had a congenital tendency toward dislocation. Dynamic US of the clenched fist is useful in diagnosing injuries of the extensor hood mechanism.

Supplemental material: *radiology.rsnajnls.org/cgi/content/full/2283020833/DC1.*

The term *boxer fracture* is a well-known eponym describing a typically transverse, minimally comminuted fracture of the little finger metacarpal shaft, with palmar angulation of the distal fragment. Boxer fracture usually results from a blow struck with the fist (1). When a blow is struck with the hand in the clenched-fist position, the metacarpophalangeal (MP) joints are very vulnerable to a spectrum of injuries (contusion, synovitis, collateral ligament injury, capsular tear). *Boxer knuckle* is a less-well-known eponym used in the sports medicine literature to describe one of the most severe and frequent types of this injury: damage to the sagittal bands of the extensor hood (2,3). The sagittal bands are transversely oriented ligaments that help stabilize the extensor tendon during joint motion (4) (Fig 1). Clinical symptoms of this type of injury include pain, swelling, loss of full joint extension, and either ulnar or radial subluxation of the extensor tendon. Subluxation is most reliably detected at palpation of the flexed joint (2); when swelling is marked or when the injury is atypical, however, subluxation may be difficult to ascertain.

The purpose of this study was to provide an initial assessment of the usefulness of dynamic US and magnetic resonance (MR) imaging in the diagnosis of sagittal band rupture in two surgically confirmed cases and in an asymptomatic volunteer with the congenital ability to dislocate the common extensor tendons.

Institutional Review Board Approval and Informed Consent

We obtained institutional review board approval for retrospective review of the medical records of patients seen within the previous year who had undergone evaluation with US prior to surgical repair of the MP extensor hood mechanism. Informed consent for review of records was not required. In addition, institutional review board approval and informed consent was obtained from, and US of the MP joints was performed on, an asymptomatic volunteer with no history of trauma.

Imaging and Surgical Procedures

US was performed by a musculoskeletal radiologist (R.L.B.) with experience in

musculoskeletal US. A 15-MHz linear transducer was used (Sequoia; Accuson, Mountain View, Calif). Focal zone, imaging depth, and postprocessing parameters were optimized for musculoskeletal imaging. The common extensor tendon dorsal to the MP joint in the affected finger and the same tendon in the contralateral, asymptomatic finger were imaged both longitudinally and in the transverse plane. Transverse US at the level of the distal metacarpal head was performed while the finger was either passively or actively flexed and extended. A standoff pad and/or a large amount of transmission gel were used.

MR imaging of the affected hand was performed on a 1.5-T unit (Signa Horizon; GE Medical Systems, Milwaukee, Wis) by using a small flexible receive coil wrapped around the hand. Transverse images of 2.5–3.0-mm-thick sections were obtained by using a T1-weighted spin-echo pulse sequence (repetition time msec/echo time msec, 750/14) and a T2*-weighted gradient-recalled-echo pulse sequence (767/17, 20° flip angle) with a small field of view, a 256 × 256 matrix, and two signals acquired. Images were obtained both with the fingers extended and with the hand in a clenched-fist position.

Surgery was performed by an experienced orthopedic hand surgeon (D.H.L.) after a review of the clinical history and results of physical examination and of imaging. The location of the sagittal band tear was identified, and the band was repaired. Adequate realignment and tracking of the extensor tendon after repair were verified by direct visualization during surgery. Clinical follow-up was performed by the same surgeon within 3–9 months after surgery.

Case Reports

Case 1

A 26-year-old right-hand–dominant policeman was wrestling with a suspect, swung a punch, and hit the ground forcefully with his right fist. He presented 1 week later with pain and swelling of the MP joint in the right long (middle) finger. At physical examination, a slight ulnar deviation of the finger and a limitation of active extension at the MP joint were observed. The dorsal side of the MP joint was markedly tender and swollen, making palpation of the extensor tendon difficult. Radiographs of the hand showed no fracture.

US of the affected MP joint demonstrated swelling in the soft tissue but normal echogenicity in the common extensor tendon. The common extensor tendon sheath in the affected joint had been displaced slightly from the dorsum toward the ulna, compared with the tendon sheath in the asymptomatic left long finger, which was centered over the dorsal metacarpal bone. With flexion of the right long finger joint, marked ulnar dislocation of the tendon was easily visualized (Fig 2). The asymptomatic common extensor tendon at the left long finger joint showed no appreciable displacement during real-time scanning throughout the full range of motion.

Surgical findings confirmed ulnar dislocation of the extensor tendon at the right long finger MP joint. A radial sagittal band longitudinal tear was identified and repaired (Fig 3).

US was performed 1 month after surgery, to verify normal postoperative appearance. The extensor tendon of the right long finger was centrally located over the dorsal metacarpal bone and evidenced no appreciable subluxation. At follow-up 9 months after surgery, the pain and swelling had resolved and the full range of flexion and extension in the MP joint had returned.

Case 2

A 49-year-old right-hand–dominant man was playing softball when he developed pain, swelling, and a slight decrease in range of motion at the MP joint in the left long finger. His medical history included surgery for repair of a torn radial sagittal band at the MP joint in the right long finger. The patient reported that the present left hand injury felt similar to the prior right hand injury. At physical examination, a moderate amount of swelling was observed over the dorsum of the MP joints of the left long finger and index finger. The range of active and passive flexion and extension of the left long finger MP joint was perceived as nearly full, but there was a slight ulnar deviation. Extensor tendon position was not noted as abnormal. Radiographs of the hand showed no fracture.

At US of the left long finger MP joint, the extensor tendons had normal echogenicity. The extensor tendon sheath of the affected knuckle was displaced slightly from the dorsum toward the ulna. With flexion of the left long finger MP joint, ulnar subluxation of the tendon was easily visualized. The asymptomatic right long finger MP joint that previously had undergone surgical repair for a torn radial sagittal band showed a small degree of ulnar displacement of the extensor tendon at scanning during full range of motion.

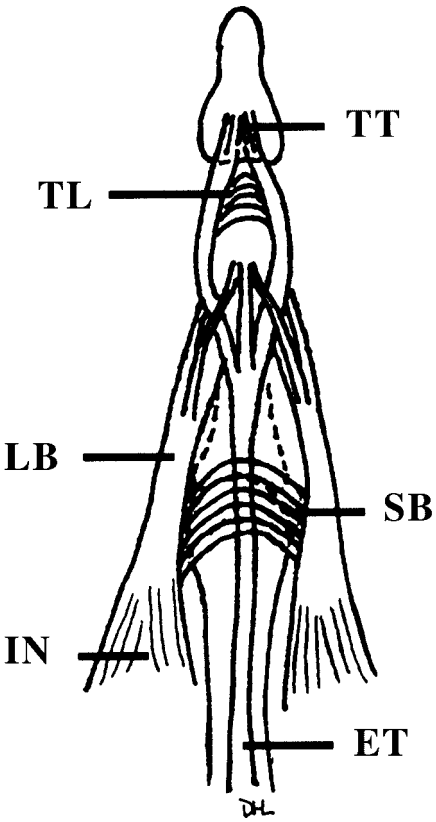

Figure 1. Diagram of the dorsal tendinous structure in the human finger. *ET* = common extensor tendon, *IN* = intrinsic muscle, *LB* = lateral band, *SB* = sagittal band, *TL* = transverse ligament, *TT* = terminal tendon.

MR imaging also was performed. T2*-weighted images showed greatly increased signal intensity in the soft tissues surrounding the extensor tendon of the left long finger MP joint (Fig 4a). The common extensor tendon and tendon sheath showed no evidence of abnormal signal intensity suggestive of tendon injury or tenosynovitis. Scanning performed with the hand in a clenched-fist position showed the ulnar displacement of the left long finger extensor tendon at the MP joint (Fig 4b).

Surgical findings confirmed the ulnar subluxation of the extensor tendon at the MP joint in the left long finger. A radial sagittal band longitudinal tear was identified and directly repaired with sutures. There was some tightness to the ulnar sagittal band, so a partial release of this structure was performed. The extensor tendon thus was realigned to normal position. Normal tracking was visualized

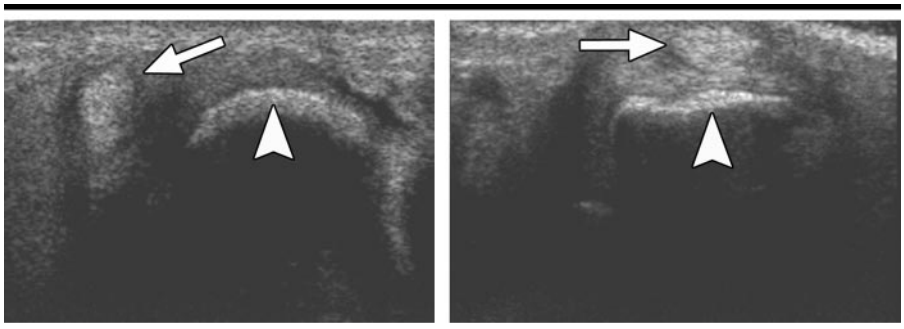

a. b.

Figure 2. Case 1. A 26-year-old right-hand–dominant man with injury to the MP joint of the right long finger. Transverse US images of **(a)** injured right long finger and **(b)** asymptomatic left long finger, acquired while the hands were in clenched-fist position, show ulnar dislocation of the right common extensor tendon (arrow in **a**) with respect to the dorsal metacarpal bone (arrowhead) but no displacement of the left common extensor tendon (arrow in **b**).

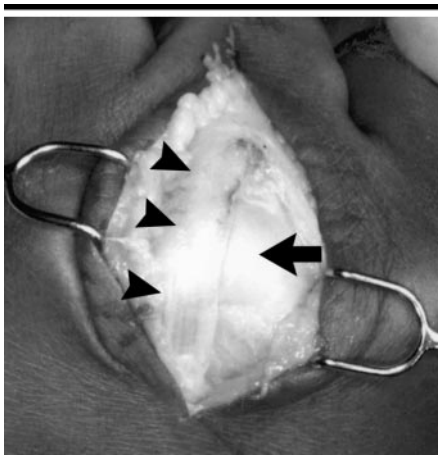

Figure 3. Case 1. Intraoperative photograph of the right long finger, taken while the hand was in clenched-fist position. Rupture of the radial sagittal band (arrow) and ulnar subluxation of the extensor tendon (arrowheads) are visible.

intraoperatively during passive range of motion.

At the last clinical follow-up visit, 4 months after surgery, the patient had resolution of pain and swelling and continued to have full range of flexion and extension of the left long finger MP joint.

Case 3

A 36-year-old right-hand–dominant woman reported the lifelong ability to dislocate the extensor tendons bilaterally with forced clenching of her fist. This was most apparent in her long and index fingers bilaterally. She had no history of trauma to the hands. There was no associated swelling or tenderness of the MP joints. She consented to US examination of her MP joints in both long fingers.

Normal echogenicity of the extensor tendons was observed at US, with no evidence of tendon injury, tenosynovitis, or soft-tissue edema. The extensor tendons were in the normal dorsal position, over the center of the long finger distal metacarpal bones, both when the fingers were fully extended and during passive flexion (Fig 5a). When the subject forcefully clenched her fists, however, the long finger extensor tendons immediately would dislocate toward the ulna (Fig 5b; Movie 1, *radiology.rsnajnls.org/cgi/content/full/2283020833/DC1*). There was no audible snap during dislocation. When the subject again extended her fingers, the tendons generally resumed their normal position over the dorsum of the metacarpal head, but sometimes she had to reposition them manually.

Discussion

The extensor hood is an aponeurotic sheet overlying the MP joint. It comprises the central extensor tendon and two distinct transverse peripheral fibers termed *sagittal bands* (2–4). Deep to this aponeurotic sheet is the joint capsule.

The common extensor tendon at the level of the MP joint consists of the superficial extensor tendon centrally and the deep extensor tendons laterally, which are tethered and kept centered over the joint during range of motion principally by the sagittal bands (2–4). The ulnar sagittal band and the radial sagittal band arise from the palmar plate and the intermetacarpal ligament at the neck of the metacarpal bone. The sagittal bands have a superficial thin layer that crosses the dorsal surface of the tendon and unites with fibers on the other side, and a thicker deep layer on both sides of the tendon that forms a groove to hold the tendon in place (4). The juncturae tendinum, fascial connections between the extensor tendons of the index finger and long finger, the long and ring fingers, and the ring and little fingers, proximal to the MP joints, also may help to stabilize the extensor tendons (2).

Injury to the sagittal bands may result in subluxation or dislocation of the extensor tendon from its normal position over the dorsum of the distal metacarpal bone. During joint flexion, the radial and ulnar sagittal bands exert tensile forces in opposite directions. If the radial band is disrupted, the unopposed action of the ulnar band on the extensor tendon will lead to ulnar-side dislocation. The imaging finding of ulnar displacement of the extensor tendon thus provides indirect evidence of a torn radial sagittal band.

The MP joint of the long finger is the site most commonly involved (2,3,5–8). Dislocation of the common extensor tendon in the long finger usually takes place in the ulnar direction. In a review of injuries to 55 fingers, all but two had ulnar-side dislocation (5). The underlying normal 10°–15° ulnar inclination of the index finger and long finger may predispose them to disruption of the radial sagittal band. In a cadaveric study, ulnar dislocation occurred after two-thirds of the radial sagittal band was transected, but only minimal radial subluxation was seen after complete transection of the ulnar sagittal band (9).

Tendon dislocation can occur also in individuals who have inflammatory joint disorders (eg, rheumatoid arthritis) that attenuate or disrupt the sagittal bands and in individuals with congenitally deficient or absent sagittal bands. Examples of the latter have been reported previously (6). Such individuals may be asymptomatic or may have associated pain and snapping.

Dislocation of the extensor tendons at the MP joint was first described by Kruckenberg in 1890 (2). The term *boxer knuckle* appears to have been used in 1957 to describe four cases of boxing-related injury to the MP joint (10). Recently reported studies of 27 extensor mechanism injuries in professional boxers showed the predominant injury to be rupture of the sagittal band with subluxation or dislocation of the common extensor tendon (2,3).

Controversy surrounds the question of what method is best for treatment of extensor mechanism disruption at the MP joint. Some advocate conservative treatment with splinting in full extension

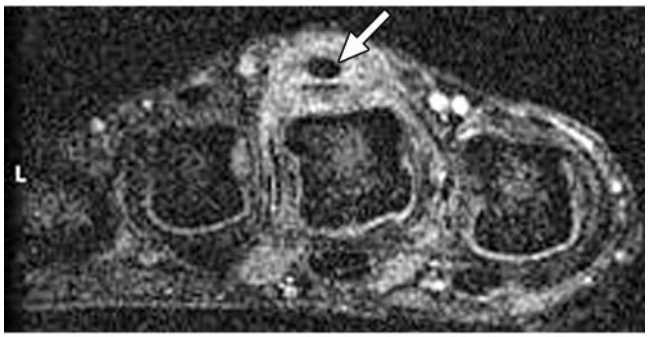

a.

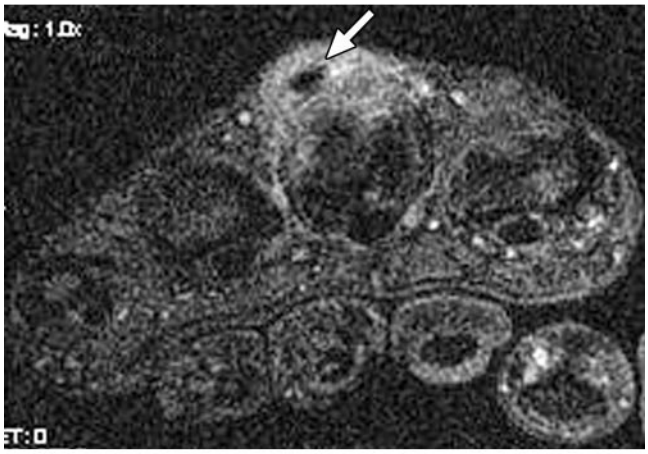

b.

Figure 4. Case 2. A 49-year-old right-hand–dominant man with injury to the MP joint in the left long finger. **(a)** Transverse T2*-weighted MR image (767/17, 20° flip angle) of left hand with fingers extended shows soft-tissue edema surrounding the common extensor tendon (arrow) in the long finger but does not depict ulnar dislocation of the tendon. **(b)** Transverse T2*-weighted MR image (767/17, 20° flip angle) of left hand with fingers clenched in a fist shows ulnar displacement of the common extensor tendon (arrow) in the long finger.

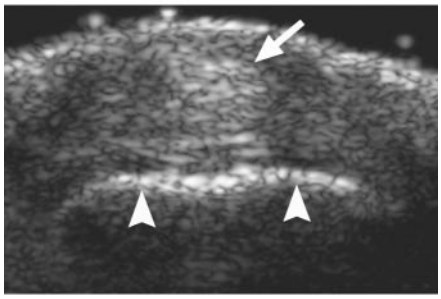

a.

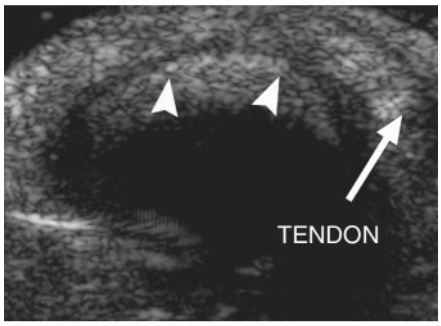

b.

Figure 5. Case 3. A 36-year-old right-hand–dominant woman with a congenital tendency to dislocate the common extensor tendons. **(a)** Transverse US image of left long finger with the fingers extended shows the common extensor tendon (arrow) in normal position with respect to the dorsal metacarpal bone (arrowheads). **(b)** Transverse US image of left long finger with the fist clenched shows nontraumatic ulnar dislocation of the common extensor tendon (arrow) with respect to the dorsal metacarpal bone (arrowheads).

(11). Others have reported that direct repair of the torn sagittal band and relocation of the central tendon is highly successful (2,3,5,6). Augmentation with tendinous slips can be performed if there is extensive tissue loss. Both of our patients with traumatic injury to the extensor tendon had successful surgical outcomes, with resolution of pain and restoration of full range of motion.

The clinical manifestation and findings at physical examination are usually sufficient to establish a diagnosis of traumatic subluxation of the extensor tendon due to injury of the sagittal band. Difficulties in diagnosis may arise, however, when the tendon position cannot be confidently palpated because of overlying soft-tissue swelling or when the clinical manifestation is atypical (ie, a full range of motion and no tendon subluxation detected at physical examination). We report two cases in which imaging played an important diagnostic role.

US has been used to detect dynamic tendon dislocation and subluxation in a variety of locations, including the hip (iliopsoas and iliotibial tendons), feet (peroneal and posterior tibial tendons), and elbow (triceps tendon) (12–15). MR imaging of joints in different kinematic positions also may provide useful information. Since the extensor tendon dislocation may not be evident with the fingers fully extended, it is important to image the MP joint during flexion. Dynamic US performed with the patient alternately extending and flexing the MP joint depicted the position change of the common extensor tendon as it occurred. This change was most dramatically evident at imaging of our asymptomatic volunteer, who could dislocate her common extensor tendon at will from the dorsum of the metacarpal head.

To our knowledge, the normal range of tendon movement in this location has not yet been demonstrated sonographically for a large cohort. A small amount of motion of the extensor tendons at the MP joint was seen in the unaffected contralateral fingers of the patients in cases 1 and 2, but the tendons did not translate completely over the dorsal metacarpal condyles during flexion. In contrast, the affected fingers had marked translation of the extensor tendon over the dorsal metacarpal condyles into the intermetacarpal space. We are unaware of any prior description of the use of US to evaluate extensor tendon dislocations at the MP joint.

Limitations of this study include the small number of subjects, which is explainable by the fact that extensor tendon dislocations are uncommon and usually manifest characteristic clinical signs and symptoms that obviate imaging. Moreover, interobserver variability could not be calculated, because only

one radiologist performed the examinations. A larger multicenter study may help to determine the sensitivity and specificity of US in establishing this diagnosis.

In our experience, dynamic US with the fingers extended and with the fist clenched enabled excellent visualization of extensor tendon subluxation and dislocation at the MP joint. MR imaging enabled similar findings in the clenched fist. However, US was our preferred modality because of its superior transverse resolution in this superficial location, its capability to depict subluxation of the tendon dynamically throughout the range of motion, and the rapidity with which a US examination can be completed.

References

1. Rogers L. The hand. In: Radiology of skeletal trauma. 2nd ed. New York, NY: Churchill Livingstone, 1992; 939–990.
2. Hame SL, Melone CP. Boxer's knuckle: traumatic disruption of the extensor hood. Hand Clin 2000; 16:375–380.
3. Hame SL, Melone CP. Boxer's knuckle in the professional athlete. Am J Sports Med 2000; 28:879–882.
4. Young CM, Rayan GM. The sagittal band: anatomic and biomechanical study. J Hand Surg [Am] 2000; 25:1107–1113.
5. Araki S, Ohtani T, Tanaka T. Acute dislocation of the extensor digitorum communis tendon at the metacarpophalangeal joint. J Bone Joint Surg Am 1987; 69:616–619.
6. Inoue G, Tamura Y. Dislocation of the extensor tendons over the metacarpophalangeal joints. J Hand Surg [Am] 1996; 21:464–469.
7. Ishizuki M. Traumatic and spontaneous dislocation of the extensor tendon of the long finger. J Hand Surg [Am] 1990; 15: 967–972.
8. Kettelkamp DB, Flatt A, Moulds R. Traumatic dislocation of the long-finger extensor tendon: a clinical, anatomical and biomechanical study. J Bone Joint Surg Am 1971; 53:229–240.
9. Koniuch MP, Primer CA, Van Gorder T, et al. Correction of ulnar subluxation of the extensor communis. Hand 1975; 7:272–274.
10. Gladden RJ. Boxer's knuckle: a preliminary report. Am J Surg 1957; 93:388–397.
11. Ritts GD, Wood MB, Engber WD. Nonoperative treatment of traumatic dislocations of the extensor digitorum tendons in patients without rheumatoid disorders. J Hand Surg [Am] 1985; 10:714–771.
12. Jacobson J, Jebson PJL, Jeffers AW, Fessell DP, Hayes CW. Ulnar nerve dislocation and snapping triceps syndrome: diagnosis with dynamic sonography—report of three cases. Radiology 2001; 220:601–605.
13. Pelsser V, Cardinal E, Hobden R, Aubin B, Lafortune M. Extraarticular snapping hip: sonographic findings. AJR Am J Roentgenol 2001; 176:67–73.
14. Miller SD, Van Holsbeeck M, Boruta PM, Wu KK, Katcherian DA. Ultrasound in the diagnosis of posterior tibial tendon pathology. Foot Ankle Int 1996; 17:555–558.
15. Diaz GC, van Holsbeeck M, Jacobson JA. Longitudinal split of the peroneus longus and peroneus brevis tendons with disruption of the superior peroneal retinaculum. J Ultrasound Med 1998; 17:525–529.