



Modern sports eye injuries

J A Capão Filipe, A Rocha-Sousa, F Falcão-Reis, et al.

Br J Ophthalmol 2003 87: 1336-1339

doi: 10.1136/bjo.87.11.1336

Updated information and services can be found at:

<http://bjo.bmj.com/content/87/11/1336.full.html>

These include:

References

This article cites 28 articles, 9 of which can be accessed free at:

<http://bjo.bmj.com/content/87/11/1336.full.html#ref-list-1>

Article cited in:

<http://bjo.bmj.com/content/87/11/1336.full.html#related-urls>

Email alerting service

Receive free email alerts when new articles cite this article. Sign up in the box at the top right corner of the online article.

Topic collections

Articles on similar topics can be found in the following collections

[Retina](#) (982 articles)

Notes

To order reprints of this article go to:

<http://bjo.bmj.com/cgi/reprintform>

To subscribe to *British Journal of Ophthalmology* go to:

<http://bjo.bmj.com/subscriptions>

SCIENTIFIC REPORT

Modern sports eye injuries

J A Capão Filipe, A Rocha-Sousa, F Falcão-Reis, J Castro-Correia

Br J Ophthalmol 2003;**87**:1336–1339

Aims: To determine the severity and long term sequelae of eye injuries caused by modern sports that could be responsible for significant ocular trauma in the future.

Methods: Prospective observational study of 24 (25 eyes) athletes with sports related ocular injuries from health clubs, war games, adventure, radical and new types of soccer, presenting to an eye emergency department between 1992 and 2002 (10 years).

Results: Modern sports were responsible for 8.3% of the 288 total sports eye injuries reported. Squash (29.2%) was the most common cause, followed by paintball (20.8%) and motocross (16.6%). The most common diagnosis during the follow up period was retinal breaks (20%). 18 (75%) patients sustained a severe injury. The final visual acuity remained <20/100 in two paintball players.

Conclusions: Ocular injuries resulting from modern sports are often severe. Adequate instruction of the participants in the games, proper use of eye protectors, and a routine complete ophthalmological examination after an eye trauma should be mandatory.

Sports related eye injuries represent a significant eye health hazard worldwide.^{1–5} Baseball and basketball have been implicated in most sports eye injuries in the United States,^{6–7} soccer in Portugal, Norway, and Israel,^{8–11} and soccer or racquet sports in Britain.^{12–16} Remarkably, few studies have attempted to elucidate other sports.

Modern sports encompass a wide variety of outdoors activities including war games, radical and adventure sports combining recreation, military manoeuvres and fantasy. The sports practised inside health clubs include squash and original forms of martial art like capoeira and yoseikan budo. Recently, new types of soccer have appeared such as intramural soccer played inside a closed field. Nowadays, these fashion sports are gaining popularity among children and adults. They are played by millions of people across Europe and around the Western world.

The purpose of this study is to outline the severity and long term sequelae of eye injuries in modern sports.

PATIENTS AND METHODS

Twenty four patients (25 injured eyes) who sustained modern sports related ocular injuries, presenting to the eye emergency department of Porto S João Hospital between April 1992 and March 2002 (10 years) were studied. The sports criteria included health clubs, war games, adventure, radical and new types of soccer.

As part of a sports ophthalmology unit, the authors performed a regular patient observation and follow up, using the United States Eye Injury Registry report forms, adapted to sports related injuries.^{9–10} Patients were followed up for at least 10 months.

RESULTS

Injuries by type of sport

The 24 modern sports injuries were 8.3% of the 288 total sports eye injuries treated at the sports ophthalmology unit. Analysis of the data showed that health club sports jointly (n = 10; 41.6%) formed the highest percentage of presentations—namely, squash (n = 7; 29.2%), capoeira (n = 1), yoseikan budo (n = 1), and bodybuilding (n = 1). They were followed by paintball (n = 5; 20.8%), motocross, (n = 4; 16.6%), and new types of soccer (n = 4; 16.6%). The latter included cases of beach soccer (n = 2), soccer volleyball (n = 1), and intramural soccer (n = 1). Finally, bungee jumping presented with one case.

Background data and demographics

Twenty two (91.7%) patients were male and two (8.3%) were female with an 11:1 male:female ratio. The mean age was 27.0 (9.2) years (range, 11–45 years). One (4%) patient was classified as paediatric (less than 18 years of age). The injuries occurred during the weekend in 16 (66.7%) cases.

Mechanism and place of injury

Most injuries resulted from impact by the ball (n = 9, 37.5%; Table 1) or paintball (n = 5, 20.8%). Injury was considered unintentional in all the patients.

No patient had a proper ocular protector in the time of the impact. Two motocross drivers, who were wearing an ocular protector and streetwear spectacles, were hit by a stone that had dislodged and broken the lens causing the lesion. It was not possible to determine the type of material of these lenses.

The paintball cases have occurred in supervised, commercial settings, where the use of eye protective devices was required. The players were hit by the paintball when they removed the eye protection (1) after being called while going to the game field; (2) because of fogging; or (3) to solve problems with their weapons.

Visual acuity

At presentation, visual acuity was less than 20/40 in eight patients (33.3%), ranged between 20/20 (12 patients), or no light perception (one patient; Fig 1). Visual acuity of two patients (8.3%) remained less than 20/100 at final follow up examination; both of these patients were paintball players. The causes of permanent visual loss were a contusion maculopathy and a corneoscleral laceration with vitreous and retinal massive haemorrhage that developed into a phthisis bulbi.

Clinical diagnosis

The left eye was significantly more frequently injured (n = 16, 64% v n = 9, 36%). One patient had a bilateral injury (the bungee jumping case).

The most common ocular tissue involvement was the anterior chamber, followed by lids/orbit and vitreous/retina (Table 2). The most common initial diagnosis was lid/orbital contusion, corneal abrasion and hyphaema, followed by retinal haemorrhage/oedema and vitreous haemorrhage. The

Table 1 Mechanism of injury by sport (n = 24)

Mechanism	Health club				New types of soccer†	Bungee jumping
	Squash	Other*	Paintball	Motocross		
Ball	6				3	
Paintball			5			
Stone				2		
Lens				2		
Racquet	1					
Foot		1			1	
Jump						1
Mousse ken		1				
Power cable		1				

Values presented as number of lesions.
 *Capoeira, yoseikan budo, and bodybuilding.
 †Beach soccer, soccer volleyball, and intramural soccer.

only case of retinal detachment was an intramural soccer player. The most frequent diagnosis during the follow up period was retinal breaks and angle recession.

Vitreoretinal lesions

At presentation, visual acuity was 20/40 or better in seven of 14 (50%) patients with vitreoretinal lesions. Also, seven of 14 (50%) patients with vitreoretinal lesions had no hyphaema. There was no association between the extension of hyphaema and the presence of vitreoretinal lesions. A similar number of vitreoretinal lesions were present in patients with or without hyphaema (63.6% v 50%). For those patients with no hyphaema there were two cases of peripheral retinal holes and one case of macular contusion.

Treatment

Nine (37.5%) patients required 11 surgical procedures. The main surgery was retinal breaks treated with argon laser photocoagulation (n = 5) followed by repair of eyelid wound (n = 2). Other surgical procedures included a repair corneoscleral rupture, a phacoemulsification (PC IOL) and a retinal detachment repair (buckle). Five (20.8%) patients required hospitalisation.

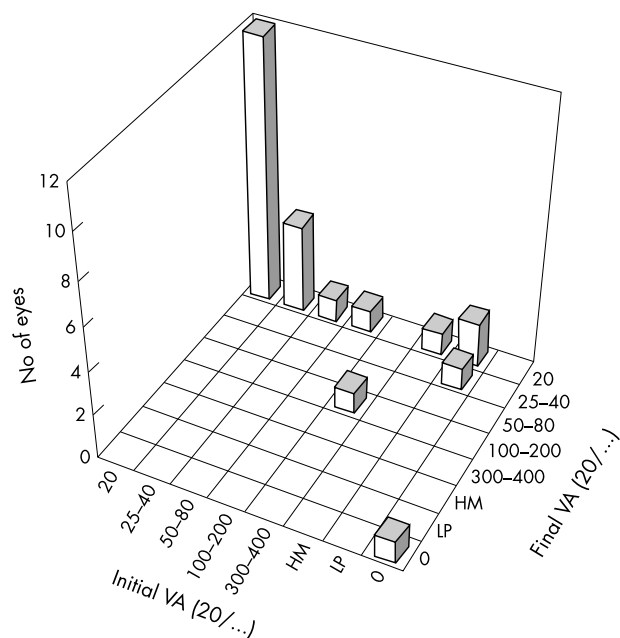


Figure 1 Initial and final best corrected visual acuity. VA = visual acuity; HM = hand movements; LP = light perception.

Severe injuries

If we define a severe injury as one requiring either hospitalisation or outpatient follow up for hyphaema or vitreous and/or retina lesion then 18 (75%) patients had severe injuries.

DISCUSSION

Modern sports injuries

In our sports ophthalmology unit, outdoor and indoor soccer were mainly responsible for the injuries; soccer is the most widespread sport in Portugal.⁹⁻¹⁰ Of eye injuries in connection with modern sports we found that 41.6% were health club related. Most of these patients had acquired the injury playing squash, a sport that, in Britain, was already one of the main offenders.¹²⁻¹⁶

The idea that only adolescents are particularly susceptible to sports injuries because of their fearless manner of play and their athletic immaturity is not true. In the present series only one player (4%) was classified as a paediatric patient as opposed to 27% and 29% of our previous studies with all sports included (namely, soccer).⁹⁻¹⁰

Clinical management

The finding that 75% of eye injuries we treated were severe, corroborate the findings of previous studies, showing that squash,¹⁷⁻¹⁸ paintball,¹⁹⁻²³ bungee jumping,²⁴⁻²⁷ and soccer⁹⁻¹⁰ injuries had resulted in an alarming number of severe ocular injuries. Retinal breaks were found in 20% of the players, a larger number compared to the 8.3% and 9.8% retinal breaks cases reported in our previous study.⁹⁻¹⁰ Any athlete suffering an eye trauma must have a complete ophthalmological examination, including gonioscopy and examination of the retinal periphery. The number of patients presenting with unsuspected vitreous and retina damage with “normal” visual acuity ($\geq 20/40 = 50\%$) and without blurred vision (no hyphaema = 50%) emphasised this.

Eye injury prevention

Unfortunately, most of these injuries could have been prevented if patients had worn adequate eye protection. The eyewear should be clearly labelled. Certification by the Protective Eyewear Certification Council (PECC: www.protecteyes.org) indicates that a protector has been tested to an American Society for Testing and Materials (ASTM) standard and that the manufacturer has had quality control certified by an independent testing laboratory.²⁸⁻³⁰ The eyewear prescribed for sports should have lenses fabricated from polycarbonate or Trivex, a new impact resistant lens material.

Squash

In squash the major area that needs to be addressed is the ignorance of the need for protective eyewear among players.³¹

Table 2 Clinical diagnosis at presentation and during the follow up period (n=25)

Diagnosis	Total	Health club		Paintball	Motocross	New types of soccer†	Bungee jumping
		Squash	Other*				
Initial diagnosis							
Lids and orbit	14 (56)	4	3	3	1	2	1
Lid/orbital contusion	13 (52)	4	3	3	1	2	
Lid oedema	1 (4)						1
Lid laceration	2 (8)	1			1		
Conjunctiva	4 (16)			1	2	1	
Subconjunctival haemorrhage	2 (8)			1	1		
Conjunctival laceration	2 (8)				1	1	
Cornea	13 (52)	4	1	2	4	2	
Corneal abrasion	12 (48)	4	1	1	4	2	
Corneoscleral laceration	1 (4)			1			
Anterior chamber	15 (60)	6	3	3	2	1	
Uveitis	4 (16)	2	1		1		
Hyphaema	11 (44)	4	2	3	1	1	
Glaucoma, secondary	3 (12)	1		1		1	
Iris prolapse	1 (4)			1			
Vitreous and retina	14 (56)	3	1	4	2	3	1
Vitreous haemorrhage	4 (16)		1	2		1	
Retinal haemorrhage	8 (32)	2	1	3		1	1
Retinal oedema	6 (24)	2		2	2		
Macular haemorrhage/oedema	3 (12)	1	1	1			
RD (rhegmatogenous)	1 (4)					1	
Choroidal haemorrhage	1 (4)			1			
Follow up diagnosis							
Angle recession	4 (16)	2			1	1	
Traumatic mydriasis	2 (8)	1		1			
Glaucoma, not controlled	1 (4)			1			
Hypotony	1 (4)			1			
Phthisis	1 (4)			1			
Cataract subluxed	1 (4)			1			
Contusion maculopathy	1 (4)			1			
Retinal break	5 (20)	2‡	1‡			2§	
Choroidal rupture	1 (4)			1			

Values presented as number of lesions (% of total). RD=retinal detachment.

*Capoeira, yoseikan budo, and bodybuilding; †beach soccer, soccer volleyball, and intramural soccer; ‡peripheral retinal tear; §peripheral retinal hole.

In many European countries, including Portugal, at health club squash courts and official competitions, the use of ocular protection is not mandatory. Safety sports eyewear that conforms to the ASTM F803 for squash is always recommended.

Paintball

Most injuries seen after 1995 occurred in non-commercial war game settings, where the use of eye protective devices is not required.³² A player should not remove the protector under any circumstance. Safety sports eyewear that conforms to the ASTM 1776 for paintball is recommended.

Motocross

In motocross, stones were impacted onto the eye through a protector when the lens dislodge or collapsed. Therefore, the use of an appropriate motocross helmet plus sports ASTM F803 or a polycarbonate face guard should be recommended.

Martial arts

Capoeira is an art form introduced by the Africans in Brazil that involves movement, music, and elements of practical philosophy. The foot reaches the eye during a ritualised combat, when two players exchange movements of attack and defence. In martial arts, standard protective eyewear is not available. Therefore, these sports are contraindicated for functionally one eyed athletes.

Soccer

There is no specific standard for soccer. Currently, eye protectors that comply with ASTM F803 for squash are recommended. We strongly recommend that protective eyewear be worn particularly for patients who require prescrip-

tion lenses, for functionally one eyed athletes, and for those who have had refractive surgical procedures that weaken the eye.

Radical sports

Retinal haemorrhages during bungee jumping occurred because of an abrupt rise of intravascular pressure in the upper portion of the body due to gravity and the sudden deceleration that occurs in the downward momentum of the bungee jumper. The whole process would be aggravated by an additional mechanism like a Valsalva retinopathy, which might happen if the jumper is scared.²⁴⁻²⁵ Bungee jumping changes in equipment, technique, and regulation are needed. Until then, this radical activity should be discouraged.

Ophthalmologist's role

The ophthalmologist's role in preventing sports related eye injuries includes providing epidemiological data on eye injuries in new sports; identifying one eyed athletes; and informing patients of the need for protective eyewear. If we ignore this guidelines we are not only guilty of ethical neglect but in some cases even of crimes punishable by law.³³

CONCLUSION

In our study we have identified the sports that could be responsible for significant ocular trauma in the future: health club sports (squash, capoeira, yoseikan budo, and bodybuilding), paintball, motocross, new types of soccer, and bungee jumping. Eye care professionals should be aware of the risks of these sports and must strongly advise participants to wear adequate eye protection. Further studies are warranted to determine the future direction and safety of these sports.

Authors' affiliations

J A Capão Filipe, A Rocha-Sousa, F Falcão-Reis, J Castro-Correia,
Department of Ophthalmology, University of Porto School of Medicine, S
João Hospital, Porto, Portugal

Correspondence to: João A Capão Filipe, MD, R Professor Luís de Pina,
162, 4150-473 Porto, Portugal; jacapaofilipe@netcabo.pt

Accepted for publication 9 March 2003

REFERENCES

- 1 **MacEwen CJ.** Eye injuries: a prospective survey of 5671 cases. *Br J Ophthalmol* 1989;**73**:888-94.
- 2 **May DR, Kuhn FP, Morris RE, et al.** The epidemiology of serious eye injuries from the United States Eye Injury Registry. *Graefes Arch Clin Exp Ophthalmol* 2000;**238**:153-7.
- 3 **McCarty CA, Fu CLH, Taylor HR.** Epidemiology of ocular trauma in Australia. *Ophthalmology* 1999;**106**:1847-52.
- 4 **Vinger PF.** The eye and sports medicine. In: Tasman W, Jaeger EA, eds. *Duane's clinical ophthalmology*, Vol 5, chapter 45. Philadelphia: JB Lippincott, 1994.
- 5 **Wong TY, Klein BEK, Klein R.** The prevalence and 5-year incidence of ocular trauma. *Ophthalmology* 2000;**107**:2196-202.
- 6 **Larrison WI, Hersh PS, Kunzweiler T, et al.** Sports-related ocular trauma. *Ophthalmology* 1990;**97**:1265-9.
- 7 **Napier SM, Baker RS, Sanford DG, et al.** Eye injuries in athletics and recreation. *Surv Ophthalmol* 1996;**41**:229-44.
- 8 **Drolsum L.** Eye injuries in sports. *Scand J Med Sci Sports* 1999;**9**:53-6.
- 9 **Filipe JAC, Barros H, Castro-Correia J.** Sports-related ocular injuries in Portugal. A three year follow-up study. *Ophthalmology* 1997;**104**:313-8.
- 10 **Filipe JAC, Fernandes VL, Barros H, et al.** Soccer-related ocular injuries. *Arch Ophthalmol* 2003;**121**:687-94.
- 11 **Pikkel J, Gelfand Y, Miller B.** [Incidence of sports-related eye injuries]. *Harefuah* 1995;**129**:249-50.
- 12 **Barr A, Baines PS, Desai P, et al.** Ocular sports injuries: the current picture. *Br J Sports Med* 2000;**34**:456-8.
- 13 **Gregory PT.** Sussex eye hospital sports injuries. *Br J Ophthalmol* 1986;**70**:748-50.
- 14 **Jones NP.** Eye injury in sport: incidence, biomechanics, clinical effects and prevention. *J R Coll Surg Edinb* 1993;**38**:127-33.
- 15 **MacEwen CJ.** Sport associated eye injury: a casualty department survey. *Br J Ophthalmol* 1987;**71**:701-5.
- 16 **Pardhan S, Shacklock P, Weatherill J.** Sport-related eye trauma: a survey of the presentation of eye injuries to a casualty clinic and the use of protective eye-wear. *Eye* 1995;**9**:50-3.
- 17 **Easterbrook M.** Ocular injuries in racquet sports. *Int Ophthalmol Clin* 1988;**28**:232-7.
- 18 **Knorr HL, Jonas JB.** Retinal detachments by squash ball accidents. *Am J Ophthalmol* 1996;**122**:260-1.
- 19 **Acheson JF, Griffiths MPF, Cooling RJ.** Serious eye injuries due to war games. *BMJ* 1989;**298**:26.
- 20 **Easterbrook M, Pashby TJ.** Eye injuries associated with war games. *CMAJ* 1985;**133**:415-9.
- 21 **Fineman MS.** Ocular paintball injuries. *Curr Opin Ophthalmol* 2001;**12**:186-90.
- 22 **Hargrave S, Weakley D, Wilson C.** Complications of ocular paintball injuries in children. *J Pediatr Ophthalmol Strabismus* 2000;**37**:338-43.
- 23 **Thach AB, Ward TP, Hollifield RD, et al.** Ocular injuries from paintball pellets. *Ophthalmology* 1999;**106**:533-7.
- 24 **Filipe JA, Pinto AM, Rosas V, et al.** Retinal complications after bungee jumping. *Int Ophthalmol* 1994-95;**18**:359-60.
- 25 **Jain BK, Talbot EM.** Bungee jumping and intraocular haemorrhage. *Br J Ophthalmol* 1994;**78**:236-7.
- 26 **Krott R, Mietz H, Kriegelstein GK.** Orbital emphysema as a complication of bungee jumping. *Med Sci Sports Exerc* 1997;**29**:850-2.
- 27 **Vanderford L, Meyers M.** Injuries and bungee jumping. *Sports Med* 1995;**20**:369-74.
- 28 **Easterbrook M.** Standards for protective eye guards. In: Torg JS, ed. *Athletic injuries to the head, neck and face*, Chapter 4. 2nd ed. St Louis: Mosby Year Book, 1991.
- 29 **Vinger PF.** Prescribing for contact sports. *Optom Clin* 1993;**3**:129-43.
- 30 **Vinger PF.** Injury prevention: where do we go from here? *J Am Optom Assoc* 1999;**70**:87-98.
- 31 **Finch C, Vear P.** What do adult squash players think about protective eyewear? *Br J Sports Med* 1998;**32**:155-61.
- 32 **Fineman MS, Fischer DH, Jeffers JB, et al.** Changing trends in paintball sport-related ocular injuries. *Arch Ophthalmol* 2000;**118**:60-4.
- 33 **Classé JG.** Medicolegal aspects. In: Zigelbaum BM, ed. *Sports ophthalmology*. Cambridge, USA: Blackwell Science, 1996:224-39.

ECHO

GAD antibodies can signal downbeat nystagmus



Please visit the
British Journal
of
Ophthalmology
website [www.bjophthalmol.com]
for a link
to the full text
of this article.

High titre glutamic acid decarboxylase (GAD) antibodies may be a reason for downbeat nystagmus (DBN), say neurologists reporting on a single case. This is the first report of a link with GAD antibodies; DBN is often associated with lesions in the brain.

The 66 year old woman presented with three months' progressive oscillopsia, blurred vision, and vertigo. She had spontaneous vertical DBN in the primary position and on lateral gaze, not inhibited by fixation, and unsteady gait veering to the right. There were no signs of neurological conditions such as stiff man syndrome (SMS) or palatal myoclonus, or of brain lesions on imaging.

GAD antibodies were present at high titre (>100 U/ml) in her serum and cerebrospinal fluid, initially and eight months later, when her symptoms were worse. They were specific for native GAD₆₅ and reacted strongly against recombinant GAD amino acid fragment 290-585 but not fragment 290-511. They also occurred in serum from patients with SMS and palatal myoclonus included for comparison and reacted similarly. Control samples from 44 blood donors were negative.

The woman underwent exhaustive tests to rule out other diagnoses. GAD antibody was detected by immunostaining and confirmed by immunoprecipitation assay of recombinant human GAD₆₅.

GAD converts glutamic acid to γ -aminobutyric acid (GABA) and is located in pancreatic β cells and GABA secreting neurones throughout the CNS. GAD antibodies occur in greater proportion in SMS and have been reported in subacute cerebellar ataxia, epilepsy, and palatal myoclonus. The cause of DBN is unknown in 40% of cases.

▲ *Journal of Neurology, Neurosurgery, and Psychiatry* 2003;**74**:998-999.