Bryan I. O'Callaghan, MD • Georges Kohut, MD • Henri-Marcel Hoogewoud, MD

Gamekeeper Thumb: Identification of the Stener Lesion with US[1]

PURPOSE: **To determine the value of ultrasound (US) in recognizing the ligamentary dislocation occasionally associated with gamekeeper thumb (Stener lesion). Detecting such dislocations is important because they require surgical repair, whereas nondisplaced ruptured ligaments respond to conservative treatment. This dislocation cannot be reliably diagnosed with standard methods, leading to unnecessary surgical procedures.**

MATERIALS AND METHODS: **Forty-eight hyperabduction injuries of the thumb were included. The thumbs were either unstable or unexaminable because of tenderness. No fractures were seen on standard radiographs.**

RESULTS: **Sonograms were positive in 13 patients, who then underwent surgery. A Stener lesion was found in 10 patients and a partial Stener lesion in three. Three patients with negative sonograms also underwent surgery, and no dislocation was found. The other 32 patients with negative US findings were treated conservatively, and none developed subsequent instability.**

CONCLUSION: **US proved to be a reliable, simple, and easily reproducible tool for recognition of the Stener lesion.**

Index terms: Fingers and toes, 437.421, 437.489 • Hand, injuries, 437.421, 437.489 • Hand, US, 437.12981 • Ligaments, injuries, 437.489

Radiology 1994; 192:477–480

[1] From the Departments of Radiology (B.I.O., H.M.H.) and Orthopaedic Surgery (G.K.), Cantonal Hospital, 1708 Fribourg, Switzerland. Received October 13, 1993; revision requested December 8; revision received April 8, 1994; accepted April 14. **Address reprint requests to** B.I.O.

HYPERABDUCTION rupture of the ulnar ligamentary apparatus of the first metacarpophalangeal (MCP) joint is a frequent and potentially severe lesion (1–3). The lesion was originally described as chronic, occurring in hunters strangling rabbits (4), and hence was known as gamekeeper thumb. However, it may occur as an acute lesion, representing up to half of all skiing injuries to the hand (5,6), and thus is also known as skier's thumb. Conservative treatment leads to unacceptably poor results (6) because of occasional rupture-associated dislocation of the proximal stump of the ligament over the adductor pollicis muscle, as originally described by Stener in 1962 (the Stener lesion) (7). Ligament healing is hampered by the interposition of the adductor pollicis muscle between the proximal and distal stumps. Therefore, the generally accepted treatment is rapid surgical repair (2,3,5,6,8), whereas that for complete but nondislocated rupture is conservative management (2,9–11).

If not properly recognized and treated, the Stener lesion leads to permanent instability of the MCP joint, requiring secondary plastic surgery of the ligament (8,12,13), or to degenerative joint disease requiring arthrodesis (14,15). A safe approach entails surgery in all unstable cases. As a result, the frequency of surgical procedures in cases in which the ligament is found to be nondisplaced is high, ranging from 48% to 85% (16). It is therefore of clinical relevance to distinguish preoperatively the simple nondislocated rupture, which can be treated conservatively, from the dislocated lesion, a true indication for surgery. Clinical examination, radiography, stress evaluation, arthrography, and magnetic resonance (MR) imaging have all been proposed as means of making the distinction. However, reliable differential diagnosis has proved difficult (2,10,11,16–23). In this study, we assessed the value of ultrasound (US) for the detection of the Stener lesion.

ANATOMY

The ulnar collateral ligamentary apparatus lies contiguous to the articular capsule. It comprises the proper and accessory collateral ligaments (Fig 1). It is covered by the dorsal aponeurotic expansion of the adductor pollicis muscle, which rises from the volar aspects of the third metacarpal, capitate, and hamate bones (Fig 2). The distal two-thirds of the ulnar collateral ligamentary apparatus are overlain by the first interosseous dorsalis muscle. This muscle has a double origin, rising from the ulnar side of the first metacarpal bone and the radial side of the second metacarpal bone. It reflects distally and ulnarly, inserting on the index finger's proximal phalanx and dorsal aponeurosis (Fig 3). In severe hyperabduction injuries, the collateral ligament may not only tear but also dislocate over the proximal edge of the adductor pollicis muscle (Fig 4).

MATERIALS AND METHODS

One fresh unembalmed cadaveric specimen was dissected to study the specific anatomic relationships. Twenty uninjured volunteers were then examined with US to determine which imaging planes were the best. We used a 128 XP machine (Acuson, Mountain View, Calif) with a 38-mm, 7.5-MHz linear probe. We purposely did not use a higher frequency probe because, although it yields better images, it is not as readily available: Our purpose was to develop a technique that makes use of standard equipment. We modified the pre- and postprocessing echographic parameters to best visualize the small parts being imaged. An agar gel pad (Sonar Aid; Geistlich-Pharma, Wolhusen, Switzerland) was occasionally useful.

Abbreviation: MCP = metacarpophalangeal.

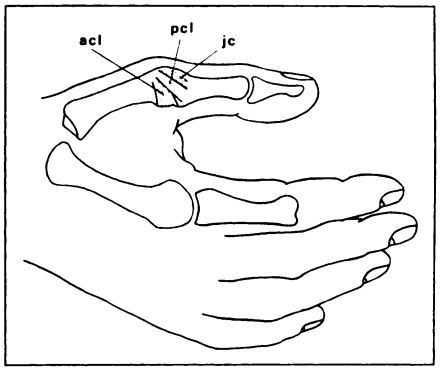

Figure 1. Ulnar collateral ligamentary apparatus of the first MCP joint. *acl* = accessory collateral ligament, *pcl* = proper collateral ligament, *jc* = joint capsule.

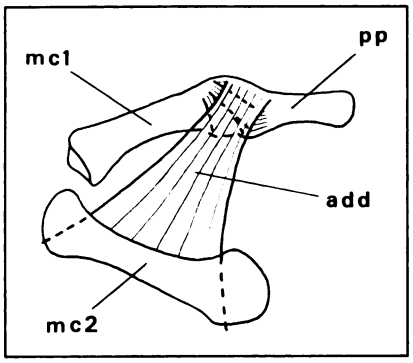

2.

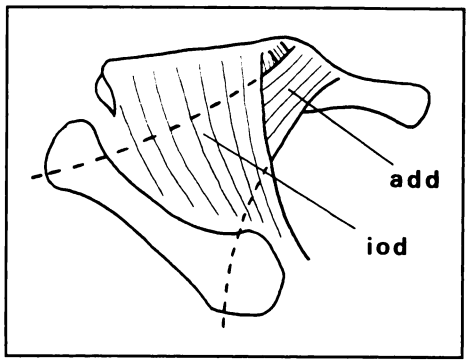

3.

Figures 2, 3. **(2)** Overlying aponeurotic expansion of the adductor pollicis muscle (*add*). *mc1*, *mc2* = first and second metacarpal bones, *pp* = proximal phalanx of the thumb. **(3)** Overlying interosseous dorsalis muscle (*iod*).

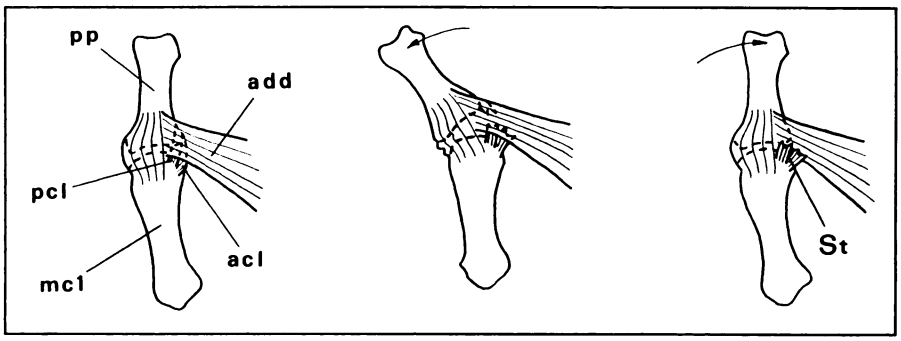

Figure 4. Mechanism of the creation of a Stener lesion (*St*) (dorsal view). *acl* = accessory collateral ligament, *add* = adductor pollicis muscle, *mc1* = first metacarpal bone, *pcl* = proper collateral ligament, *pp* = proximal phalanx of the thumb. Arrows indicate the direction of hyperabduction stress followed by usual spontaneous reduction.

We studied 48 patients with hyperabduction injury to the MCP who were admitted to the emergency department at our hospital between April 1992 and September 1993. Twenty-five injuries resulted from skiing, eight from other sports, eight from construction work, five from falls (related to other occupations), and two from other causes. There were 33 male and 15 female subjects, ranging in age from 7 to 89 years, with a mean age of 28 years.

The clinical evaluation was performed by the orthopedic surgeon. Patients with radial instability were included in this study, as were those having suffered hyperabduction trauma but whose MCP joint stability was unassessable because of tenderness. Clinical instability of the MCP joint was assessed in extension and 20° of flexion, as were the modifications of these findings with joint supination. The decision to perform surgery was made solely on the basis of the clinical findings when there was reasonable doubt regarding the integrity of the ligament. Standard posteroanterior and profile radiographs were obtained. We did not perform any clinical examinations with use of local anesthetics, nor did we perform any stress radiographic examinations. Patients with exclusive volar pain on hyperextension (suggestive of volar plate damage) or associated thumb phalangeal or metacarpal fractures were excluded from the study.

Of the 48 patients, 16 underwent surgery. Surgical repair was performed by reinsertion or suture of the torn ligaments, with use of resorbable monofilament suture. The thumb was then immobilized in a cast for 4 weeks, followed by MCP protection in a thermomalleable orthosis for an additional 4 weeks. The remaining 32 patients were treated conservatively with use of an orthosis for 6 weeks. The stability of the MCP joint was clinically tested 3 months after the trauma.

US was performed by the radiologist. Except in three patients who presented 1 week after injury, US was performed within 48 hours of trauma in all patients. The first web was examined from a dorsal transverse approach (Fig 5) and scanned proximal to distal (Figs 6, 7). If a Stener lesion was present, it was seen as a hyperechoic, 5-mm rounded structure, surrounded by a hypoechoic halo, lying on the dorsal aspect of the adductor pollicis muscle just distal to the distal edge of the first interosseous muscle (Fig 8). We found that displaced ligaments were best seen on transverse scans, the longitudinal views having only a confirmatory role in cases of doubt. The tendon of the extensor pollicis longus muscle may occasionally have a similar appearance in this transverse plane, and the differentiation is easily made by examining the longitudinal aspect of the structure, the image of which remains rounded in the case of a Stener lesion.

RESULTS

Sonograms were positive in 13 cases. Surgical findings confirmed the US diagnosis of Stener lesion in 10 of these 13 (Fig 9). In the remaining three cases, a partial ligament rupture was found at surgery, the ruptured portion being dislocated over the adductor muscle. In each case, an associated capsular tear was noted, with fragments dislocated in a manner similar to that in the Stener lesion.

Three patients with unstable thumbs but with negative sonograms nevertheless underwent surgery. Ligamentary rupture was found (hence the instability), but no dislocations were noted. None of the 32 patients with negative sonograms who were treated conservatively were found to have developed instability at the 3-month clinical evaluation.

DISCUSSION

Physical examination of the MCP joint of the injured thumb may be difficult because of edema and tenderness, which can produce a false impression of stability or render the digit unexaminable. Because the ligament is ruptured whether the injury is a simple nondislocated rupture or a true Stener lesion, clinical instability is present and is therefore of no help in distinguishing between the two lesions. Although palpation of the dislocated proximal stump of the ligament is sometimes possible (2), this finding must be considered unreliable, since such precise evaluation is seldom feasible on a painful or swollen thumb. Furthermore, the false-negative rate can be as high as 46% (16).

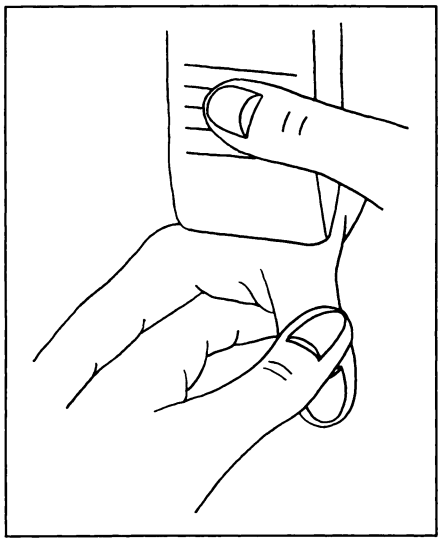

Figure 5. Position of probe used to evaluate the Stener lesion (dorsal transverse approach).

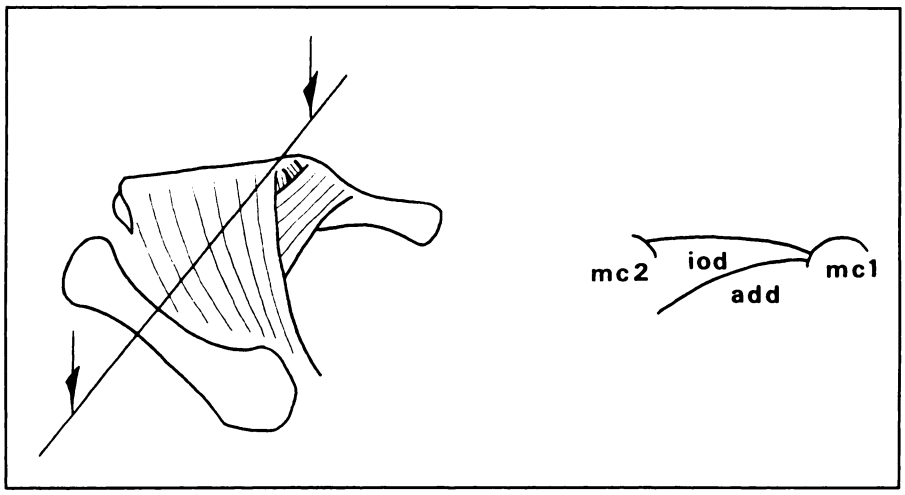

Figure 6. Diagram of normal US examination of the first web, proximal to the reflection of the interosseous dorsalis muscle (*iod*) from the first metacarpal bone (*mc1*). All US scans are viewed from the distal end. *add* = adductor pollicis muscle, *mc2* = second metacarpal bone. Arrows indicate the direction of the US examining plane.



a. b.

Figure 7. **(a)** Diagram and **(b)** real-time sonogram show a normal first web, distal to the reflection of the interosseous dorsalis muscle (*iod*, curved arrow in **b**) from the first metacarpal bone (*mc1*, straight arrow in **b**); no lesion is seen between the two. *add* = adductor pollicis muscle, *mc2* = second metacarpal bone. Arrows in **a** indicate the direction of the US examining plane.

Standard radiographs, while enabling an associated fracture to be excluded, do not enable distinction between a nondislocated ligament and a true Stener lesion. Various abduction-stress radiographs, sometimes taking into account both MCP extension and flexion instability, with and without comparative views, have been proposed (10,11,16), occasionally with use of custom-made holding devices (17,18). These methods cannot, however, be used to distinguish reliably between the two lesions. Furthermore, the joint opening angle at clinical examination and that seen on the stress radiograph correlate poorly (10,16). Moreover, repeated stress evaluations can cause severe damage (eg, to complete a partial or healing tear or dislocate a torn but nondislocated ligament) (11,19,20).

Arthrography has also been proposed: The absence of an imprint by the ligament on the articular capsule, occasionally with leakage of contrast material signifying a capsular tear, may indicate a Stener lesion (21,24). The reliability of this invasive method has yet to be established, however, and it seems that ligamentary damage and capsular tear should be regarded as two independent entities (25). Our experience certainly supports that conclusion. MR imaging of the dislocated proximal stump has also been attempted but in some studies has yielded poor results (19,20,22). However, its potential has probably not yet been fully explored and may improve with high-resolution small-parts coils.

In our study, in the three cases in which the surgeon found an incompletely torn ligament, the proximal stumps of both the partially ruptured ligament and the articular capsule were found between the interosseous and adductor muscles, thus mimicking a Stener lesion. We do not know how these patients would have fared without surgical management, although they would probably have undergone surgery in any case, even if the precise nature of their lesion had been known preoperatively.

Because no preoperative diagnostic standard of reference exists for this lesion and because it is ethically out of the question to operate on all patients for the sole purpose of clarifying the preoperative diagnosis, precise figures for sensitivity and specificity cannot be given. However, all of the positive US findings were confirmed at surgery. Specificity can be truly assessed only in the three cases in which the findings at surgery correlated with the preoperative diagnosis of the ligament's nondislocation. None of the 32 patients with negative US findings who were treated conser-



a. b.

Figure 8. **(a)** Diagram and **(b)** real-time sonogram of a Stener lesion (*St*) show a hyperechoic lesion with a hypoechoic halo (arrowheads in **b**) lying between the interosseous dorsalis muscle (*iod*, curved arrow in **b**) and the first metacarpal bone (*mc1*, straight arrow in **b**), which corresponds to the dislocated ligament. *add* = adductor pollicis muscle, *mc2* = second metacarpal bone.

vatively developed subsequent instability. The results reported in the literature would therefore allow us to conclude that these were truly nondislocated lesions (2,10,26–28).

In this small series, US proved to be a simple and reliable tool for the preoperative detection of the Stener lesion. It enables the immediate, noninvasive distinction between patients who require surgery and those who do not, thus avoiding many unnecessary surgical procedures. Detection of the dislocated ligament seems easy, requiring neither an expert in US nor extensive training once the anatomic relationships described herein are understood. A further prospective study is under way to assess more fully the sensitivity and specificity of this technique, including its possible pitfalls and its application in cases of chronic injury and nondisplaced ligamentary damage. Comparison with other diagnostic techniques should be valuable. ■

Acknowledgments: We are indebted to Peter Stutz, MD, Otmar Hersche, MD, and Martin Köppel, MD, from the Orthopaedic Surgery Department of the Cantonal Hospital, Fribourg, Switzerland, for their help in completing this work. We also thank James Grainger for his help with photography.

Figure 9. Perioperative view of a Stener lesion (arrowheads) in the same patient as Figure 8.

References

1. Massart P, Bezes H. Severe metacarpophalangeal sprain of the thumb in surgical repairs in a group of 340 cases of metacarpophalangeal sprains from skiing accidents. Ann Chir Main Memb Super 1984; 3:101–112. [French]
2. Abrahamsson SO, Sollerman C, Lundborg G, Larsson J, Egund N. Diagnosis of the displaced collateral ligament of the metacarpophalangeal joint of the thumb. J Hand Surg [Am] 1990; 15:457–460.
3. Moutet F, Guinard D, Lebrun C, Bello-Champel P, Massart P. Metacarpophalangeal thumb sprains based on experience with more than 1000 cases. Ann Chir Main Memb Super 1989; 8:99–109. [French]
4. Campbell CS. Gamekeeper's thumb. J Bone Joint Surg [Br] 1955; 37:148–149.
5. Gerber C, Fernandez DL, Matter P. Winter sport injuries to the hand. Schweiz Z Sportmed 1981; 29:129–136. [German]
6. Gerber C, Senn E, Matter P. Skier's thumb: surgical treatment of recent injuries to the ulnar collateral ligament of the thumb's metacarpophalangeal joint. Am J Sports Med 1981; 9:171–177.
7. Stener B. Displacement of the ruptured ulnar collateral ligament of the metacarpophalangeal joint of the thumb. J Bone Joint Surg [Br] 1962; 44:869–879.
8. Arnold DM, Cooney WP, Wood MB. Surgical management of chronic ulnar collateral ligament insuffiency of the thumb metacarpophalangeal joint. Orthop Rev 1992; 5:583–588.
9. Kuhlmann JN, Mortier JP, Kirsch JM, Mimoun M, Boabighi A, Baux S. Entorses invétérées métacarpophalangiennes du pouce: classification anatomo-clinique et conséquences thérapeutiques. Rev Chir Orthop 1988; 74:446–453.
10. Bowers WH, Hurst LC. Gamekeeper's thumb: evaluation by arthroscopy and stress roentgenography. J Bone Joint Surg [Am] 1977; 59:519–524.
11. Louis DS, Huebner JJ Jr, Hankin FM. Rupture and displacement of the ulnar collateral ligament of the metacarpophalangeal joint of the thumb: prospective diagnosis. J Bone Joint Surg [Am] 1986; 68:1320–1326.
12. Breek JC, Tan AM, van Thiel TP, Daantje CR. Free tendon grafting to repair the metacarpophalangeal joint of the thumb: surgical technique and a review of 70 patients. J Bone Joint Surg [Br] 1989; 71:383–387.
13. Lamb DW, Angarita G. Ulnar instability of the metacarpophalangeal joint of the thumb. J Hand Surg [Br] 1985; 10:113–114.
14. Reikeras O, Kvarnes L. Rupture of the ulnar ligament of the metacarpophalangeal joint of the thumb. Arch Orthop Trauma Surg 1982; 100:175–177.
15. Neviaser RJ, Wilson JN, Leviano A. Rupture of the ulnar collateral ligament of the thumb (gamekeeper's thumb): correction by dynamic repair. J Bone Joint Surg [Am] 1971; 54:1357–1364.
16. Heyman P, Gelberman RH, Duncan K, Hipp JA. Injuries of the ulnar collateral ligament of the thumb metacarpophalangeal joint. Clin Orthop 1993; 292:165–171.
17. Hildebrandt HD. Holding device for x-ray determination of injuries in collateral ligaments of the metacarpophalangeal joint of the thumb. Handchir Mikrochir Plast Chir 1983; 15:194–195. [German]
18. Van Wetter P. Diagnostic des ruptures du ligament collatéral de l'articulation métacarpophalangienne du pouce: présentation d'un test clinique et radiologique simple. Ann Chir Main Memb Super 1986; 5:135–138.
19. Louis DS, Buckwalter KA. Magnetic resonance imaging of the collateral ligaments of the thumb. J Hand Surg [Am] 1989; 14:739–741.
20. Spaeth HJ, Abrams RA, Bock GW, et al. Gamekeeper thumb: differentiation of the nondisplaced and displaced tears of the ulnar collateral ligament with MR imaging. Radiology 1993; 188:553–556.
21. Resnick D, Danzig LA. Arthrographic evaluation of injuries of the first metacarpophalangeal joint: gamekeeper's thumb. AJR 1972; 126: 1046–1052.
22. Hinke DH, Erickson SJ, Timins ME, Chamoy L. MRI of the first metacarpophalangeal joint: normal anatomy and evaluation of "gamekeeper's thumb." Presented at the 93rd Annual Meeting of the American Roentgen Ray Society, San Francisco, Calif, April 19–24, 1993.
23. Downey EF Jr, Curtis DJ. Patient-induced stress test of the first metacarpophalangeal joint: a radiographic assessment of collateral ligament injuries. Radiology 1986; 158:679–683.
24. Engel J, Ganel A, Ditzian R, Militeanu J. Arthrography as a method of diagnosing tear of the ulnar collateral ligament of the metacarpophalangeal joint of the thumb. J Trauma 1979; 19:106–109.
25. Pichora DR, McMutry RY, Bell MJ. Gamekeeper's thumb: a prospective study of functional bracing. J Hand Surg [Am] 1989; 14:567–573.
26. Lamb DW, Abernathy PJ, Fragiadakis E. Injuries of the metacarpophalangeal joint of the thumb. Hand 1971; 3:164–168.
27. McCue FC, Hakala MW, Andrews JR, Gieck JH. Ulnar collateral ligament injuries of the thumb in athletes. J Sports Med 1974; 2:70–80.
28. Dray GJ, Eaton RG. Dislocation of the digits. In: Livingstone C, ed. Operative hand surgery. 2nd ed. New York, NY: Green, 1988; 793–797.