*Scand J Med Sci Sports 2007; 17: 387–392*
*Printed in Singapore. All rights reserved*
*DOI: 10.1111/j.1600-0838.2006.00579.x*



SCANDINAVIAN JOURNAL OF
MEDICINE & SCIENCE
IN SPORTS

# Anatomy of the anterior cruciate ligament double bundle structure: a macroscopic evaluation

**H. Steckel[1,2], J. S. Starman[1], M. H. Baums[2], H. M. Klinger[2], W. Schultz[2], F. H. Fu[1]**

*[1]Department of Orthopaedic Surgery, University of Pittsburgh, Pittsburgh, Pennsylvania, USA, [2]Department of Orthopaedic Surgery, University of Göttingen, Göttingen, Germany*
*Corresponding author: Hanno Steckel, Robert-Koch-Str. 40, 37075 Gröttingen, Germany. Tel: +49 551 392782, Fax: +49 551 395562, E-mail: hanno.steckel@gmail.com*

Accepted for publication 24 May 2006

***Introduction:*** **Traditional anterior cruciate ligament (ACL) surgery has demonstrated good results, but there is still a subset of unsatisfactory outcomes. Trends in reconstruction technique have changed from bone–patella–tendon–bone to hamstring refixation, and the next step appears to be the double bundle concept.** ***Methods:*** **We examined six fresh-frozen cadaver knees to evaluate the double bundle structure, dynamic motion characteristics and the relationship of knee flexion and relative position of the femoral insertion sites of the ACL.** ***Results:*** **In all knees, we identified an anteromedial (AM) and posterolateral (PL) bundle. The motion pattern demonstrated that the AM and PL bundles are oriented near parallel with the knee extended, and twist around each other as the knee is flexed. The visualization of the femoral footprint anatomy differs with knee flexion.** ***Discussion:*** **The double bundle model facilitates restoration of the original footprint anatomy and biomechanics more easily than the concept of the ACL as a one-bundle structure and the use of the o'clock position. It is essential to be aware of the degree of knee flexion when drilling the femoral tunnels.** ***Perspective:*** **Anatomic ACL reconstruction is a concept, not a technique, and allows a more refined surgical approach to ACL reconstruction including revision cases and partial ACL tears.**

Anterior cruciate ligament (ACL) tear is a common injury in orthopedic sports medicine (Brown et al., 1999). Conservative treatment does not restore the normal ACL anatomy, and results in the development of early osteoarthritis due to anterior–posterior (AP) and rotational instability. Therefore, surgical reconstruction is the preferred choice in management. Current techniques in ACL surgery have been associated with satisfactory long-term results in the majority of patients; however, there remains a subset, up to 30% of patients and more, with unsatisfactory outcomes. Specifically, patients report difficulties relating to rotational instability and return to previous level of activity (Gerich et al., 1997; Bach et al., 1998; Brandsson et al., 2000; Anderson et al., 2001b; Goldblatt et al., 2005). Techniques in ACL reconstruction have progressed over time. The most widely accepted graft choice has changed from bone–patella–tendon–bone to hamstring, which is associated with less donor site morbidity (Sanchis-Alfonso et al., 1999; Eriksson et al., 2001; Kartus et al., 2001). The next step in refining surgical technique in ACL reconstruction appears to be the double bundle technique (DBT), which aims at restoring the original anatomy and footprints of the ACL by reconstructing the anteromedial (AM) and posterolateral (PL) bundle of the ACL (Muneta et al., 1999; Hara et al., 2000; Yasuda et al., 2004; Cha et al., 2005). This is in contrast to the single bundle technique (SBT), which attempts to restore the fibers of the AM bundle. The presence of a double bundle anatomy in the ACL is still controversial. While some authors describe the ACL as one continuous structure (Odensten & Gillquist, 1985), others describe two bundles (Girgis et al., 1975; Arnoczky, 1983) or even three bundles (Amis & Dawkins, 1991; Hollis et al., 1991). Restoration of native ACL anatomy and normal knee kinematics is the basic goal in all ACL reconstruction techniques. In radiostereometric studies (RSA), Brandsson et al. (2002) pointed out that knee kinematics following ACL rupture become abnormal as demonstrated by changes in joint loads, and that ACL reconstruction fails to restore normal kinematics. Therefore, there has been a trend in SBT from a more vertical reconstruction to a position closer to the oblique femoral attachment of the ACL, in order to restore a more normal knee rotational stability (Loh et al., 2003; Scopp et al., 2004). In addition to this, Musahl et al. (2005) demonstrated that a femoral tunnel position within the anatomical footprint results in knee kinematics closer to the intact knee than a graft

placed at a position for best graft isometry. Thus, it seems reasonable to reconstruct the ACL footprint anatomy by placing two bundles, one closer to the vertical position and one closer to the horizontal position, in order to achieve both AP and rotational stability.

The aim of this study is to describe the relationship of flexion degree and the relative position of the AM and PL insertion sites, as the visualization of the femoral attachment sites of both bundles changes with different degrees of knee flexion and does not seem to receive enough consideration. To provide information for graft choice and landmarks for tunnel placement, we demonstrate the double bundle structure, the femoral and tibial attachment sites, the length and width of the AM and PL bundles and the tensioning pattern of each bundle.

## Material and methods

We obtained six fresh-frozen cadaver knees (two females, four males), aged from 24 to 40 years, with an average age of 30 years. The specimens obtained had approximately 200 mm of femur and tibia. There were three left and three right knees. Skin, muscles, patella, patella tendon and the joint capsule were removed; however, the passive stabilizing structures of the joint, including the ACL, PCL, medial and lateral meniscus and the collateral ligaments, were left intact. A preparation of the ACL was completed in order to identify and separate the AM and PL bundle. Next, flexion–extension and rotation motion was assessed before and after removal of the PCL and the medial femoral condyle with a testing machine, in order to visualize the motion patterns of the two bundles. Following completion of this step, we marked the femoral and tibial attachment area with a pen. After removal of the AM and PL bundle, the center of the femoral insertion site of each bundle was also marked. We assessed the angle formed between a horizontal line and a line connecting the center of the fermoral insertion of each bundle at 0°, 30°, 60°, 90°, 120° and 150° of knee flexion. Individual bundle length and width were measured using a standard micrometer. We defined the length of each bundle as the distance between the central points of the femoral and tibial attachments. Width was measured at the midpoint of each bundle. The cross-sectional area of each bundle was defined by transecting each bundle at its midpoint. Next, the cross-sectional area, the AM and PL insertion sites on the femoral and tibial attachments were measured using digital photographs. Finally, digital photographs were also taken of the femoral insertion site at each of the defined knee flexion angles to assess the angle created by the lines connecting AM insertion, PL insertion and the horizontal plane. For statistical analysis, we reported the ranges and the mean of our measurements.

## Results

In all six knees, we were able to identify an ACL with an AM and PL bundle, which we divided surgically for better distinction. The femoral insertion site of the whole ACL was semilunar at the posterior part of the inner surface of the lateral condyle with an attachment length of 13–25 mm and a width of 6–13 mm. The AM bundle originated from the anterior–proximal aspect and the PL bundle from the posterior–distal aspect of the femoral attachment with the leg in extension. The cross-sectional area increased from the femur to the tibia. The tibial insertion site of the whole ACL was located anterior and lateral to the medial tibial spine with a width between 9 and 14 mm and an AP length of 17–25 mm. The AM bundle insertion was located at the anteromedial and the PL bundle insertion at the posterolateral aspect of the tibial attachment (Figs 1 and 2). In each knee, we observed a close approximation of the PL bundle to the posterior root of the lateral meniscus, including some common attachment fibers (Fig. 3). The range and means of the AM bundle measurements are shown in Tables 1a and 1b and in Fig. 4(a). Data concerning the PL bundle are demonstrated in Tables 2a and 2b and in Fig. 4(b).

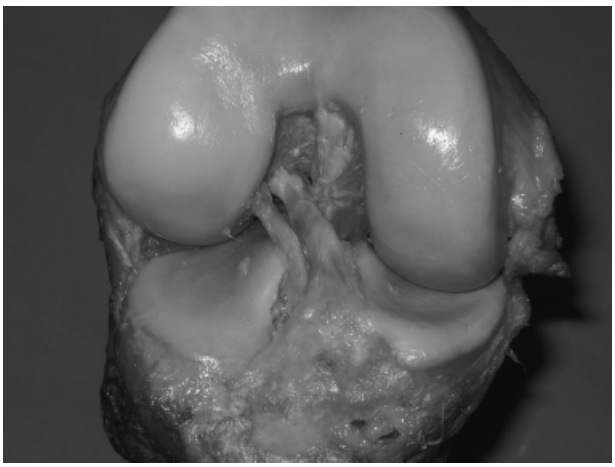

*Fig. 1.* Anterior cruciate ligament double bundle structure of a cadaver knee, anterior view.

*Fig. 2.* Anterior cruciate ligament double bundle structure of a cadaver knee, posterior view.

Table 1. AM bundle measurements

| Knee number | Age | Sex | Side | AM | | | | |
|---|---|---|---|---|---|---|---|---|
| | | | | Length (mm) | Width (mm) | Midsubstance ($mm^2$) | Femoral attachment ($mm^2$) | Tibial attachment ($mm^2$) |
| (a) | | | | | | | | |
| 1 | 40 | M | L | 37 | 6 | 16 | 62 | 65 |
| 2 | 40 | M | R | 38 | 8 | 18 | 63 | 66 |
| 3 | 24 | M | L | 34 | 10 | 23 | 70 | 72 |
| 4 | 24 | M | R | 36 | 10 | 24 | 72 | 75 |
| 5 | 26 | F | L | 40 | 8 | 20 | 64 | 68 |
| 6 | 26 | F | R | 41 | 9 | 21 | 65 | 70 |

| | AM | | | | |
|---|---|---|---|---|---|
| | Length (mm) | Width (mm) | Midsubstance ($mm^2$) | Femoral attachment ($mm^2$) | Tibial attachment ($mm^2$) |
| (b) | | | | | |
| Range | 34–41 | 6–10 | 16–24 | 62–72 | 65–75 |
| Average | 37.7 | 8.5 | 20.3 | 66 | 69.3 |

M, male; F, female; L, left; R, right; AM, anteromedial.

*Fig. 3.* Common attachment fibers of posterolateral (PL) bundle and posterior lateral meniscus.




*Fig. 4.* (a) Anteromedial bundle; (b) posterolateral bundle.

Motion pattern observation of the AM and PL bundle, obtained using our testing machine before and after removal of the PCL and the medial femoral condyle, showed tightening of the AM bundle as the knee was flexed toward 90°, and a tightening of the PL bundle as the knee was extended and when internal rotation was applied at 90° flexion. While AM and PL appeared parallel in the sagittal plane with the knee at full extension, the two bundles twisted around each other with increasing degrees of knee flexion (Fig. 5a, b). The measurements of the angle between the line connecting the centers of the AM and PL insertion and a horizontal line are demonstrated in Table 3.

## Discussion

Our macroscopic evaluation showed that the double bundle structure can be well distinguished in the ACL, as described by Girgis et al. (1975) and Arnoczky (1983). However, this study reveals the importance of the correlation of knee flexion and femoral insertion site position. It is important to remember that the anatomical description is given with the knee in full extension (Fig. 5a), while surgery is completed with the knee in flexion (Fig. 5b). With the knee in normal position for arthroscopy, flexion degrees between 70° and 100° are reached. In this position, the PL bundle is visualized anterior–distal

Table 2. PL bundle measurements

| Knee number | Age | Sex | Side | PL | | | | |
|---|---|---|---|---|---|---|---|---|
| | | | | Length (mm) | Width (mm) | Midsubstance ($mm^2$) | Femoral attachment ($mm^2$) | Tibial attachment ($mm^2$) |
| (a) | | | | | | | | |
| 1 | 40 | M | L | 19 | 6 | 14 | 44 | 50 |
| 2 | 40 | M | R | 21 | 7 | 14 | 46 | 48 |
| 3 | 24 | M | L | 17 | 9 | 20 | 59 | 63 |
| 4 | 24 | M | R | 18 | 9 | 21 | 60 | 63 |
| 5 | 26 | F | L | 24 | 7 | 18 | 52 | 54 |
| 6 | 26 | F | R | 25 | 8 | 19 | 53 | 56 |

| | PL | | | | |
|---|---|---|---|---|---|
| | Length (mm) | Width (mm) | Midsubstance ($mm^2$) | Femoral attacment ($mm^2$) | Tibial attachment ($mm^2$) |
| (b) | | | | | |
| Range | 17–25 | 6–9 | 14–21 | 44–60 | 48–63 |
| Average | 20.7 | 7.7 | 17.7 | 52.3 | 55.7 |

PL, posterolateral; M, male; F, female; L, left; R, right; AM, anteromedial.

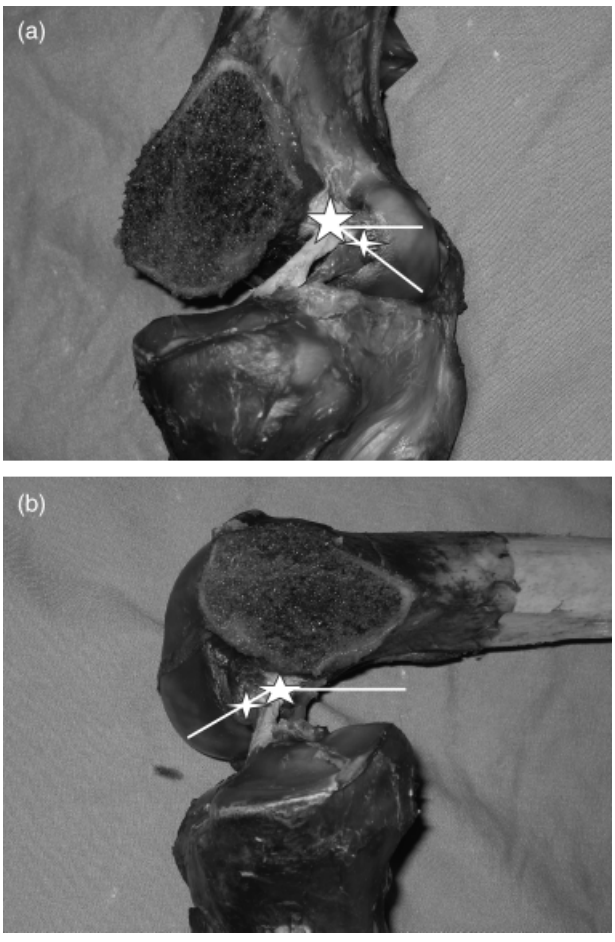


*Fig. 5.* (a, b) Anteromedial and posterolateral bundles parallel with the knee in extension and twisted with the knee in flexion, femoral insertion sites marked, angle between horizontal line and line connecting the center of each bundle marked.

to the AM bundle. Bending the knee toward 120°–150°, a more horizontal position of the bundles insertion sites is reached. The description of the femoral insertion site using the o'clock position is only helpful in the frontal plane (Sommer et al., 2000), but does not account for the three-dimensional nature of the femoral attachment, especially when the double bundle concept is applied. Furthermore, the intercondylar notch measurements and descriptions differ significantly among different authors (Souryal et al., 1988; Shelbourne et al., 1997; Teitz et al., 1997; Anderson et al., 2001a, b).

As described in the literature, we found the orientation of the AM and PL bundle to be parallel in the sagittal plane with the knee at full extension, and twisted as the knee was flexed toward 90° (Hollis et al., 1991; Duthon et al., 2005; Takashi et al., 2006). This observation is a critical point for surgical considerations, because of the flexed knee position used during standard arthroscopy. In our study, the AM bundle tightened as the knee was flexed toward 90°, while the PL bundle tightened as the knee was extended. In a cadaveric study, Sakane et al. (1997) reported a higher *in situ* force in the PL bundle at 0° and 15°, and a higher *in situ* force in the AM bundle at 90° knee flexion, which was confirmed in biomechanical evaluations by Amis and Dawkins (1991) and Gabriel et al. (2004). The forces within the fibers and bundles change throughout flexion and extension (Takai et al., 1993; Zaffagnini et al., 2004). Therefore, tensioning of the AM bundle should be in approximately 90° flexion and the PL bundle in a position near full extension.

Consistent with the existing literature, we found the femoral insertion site of the whole ACL to be semilunar at the posterior part of the inner surface of

Table 3. Angle measured between a horizontal line and the line connecting the center of the femoral insertion of the AM and PL bundle in the sagittal plane

| Knee flexion. | 0° | 30° | 60° | 90° | 120° | 150° |
|---|---|---|---|---|---|---|
| Angle | 55.2 | 79.2 | 105.7 | 136.8 | 170.2 | 205.8 |
| Range | 49–60° | 71–85° | 98–111° | 131–141° | 167–174° | 202–210° |

AM, anteromedial; PL, posterolateral.

the lateral condyle, with the same range of attachment length (Bernard et al., 1997; Giron et al., 2005; Takashi et al., 2006). The AM and PL bundle originated from the anterior–proximal and posterior–distal aspect of the femoral attachment. With respect to the cross-sectional area of the whole ACL, we observed an increase from the femur to the tibia. The AM bundle inserted anteromedial and the PL bundle posterolateral, as previously reported (Girgis et al., 1975; Arnoczky et al., 1983; Amis & Dawkins, 1991; Dienst et al., 2002; Petersen et al., 2002). Our observation of the characteristics of each bundle showed that the AM bundle and the PL bundle measurements were in agreement with the literature (Kennedy et al., 1974; Kummer & Yamamoto, 1988; Amis & Dawkins, 1991; Hollis et al., 1991). Although there are good literature data concerning the width of the whole ACL, measuring between 7 and 12 mm (Amis & Dawkins, 1991), there is no good literature database concerning the midsubstance width and cross-sectional area of the AM and PL bundle individually. In contrast to Duthon et al. (2005), we found the AM bundle to be thicker than the PL bundle on average. Our measurements of the cross-sectional areas of the AM and PL bundle at their attachment sites were within the data described by Harner et al. (1999) and Takashi et al. (2006). At the femoral attachment, findings differ concerning the AM and PL bundle sizes; however, at the tibial attachment there appears to be agreement that the AM bundle has a greater attachment, area than the PL bundle. As described by Girgis et al. (1975), we found the PL bundle and the posterior root of the lateral meniscus to have some common attachment fibers. As the PL bundle is often obscured by the AM bundle, the posteror root of the lateral meniscus is an important landmark for tibial PL tunnel placement, especially when only the PL bundle is replaced.

As descriptions of the tibial and femoral anatomical footprints differ within the literature, the location of the remaining ACL fibers of each patient should be examined closely at the time of surgery to ensure proper restoration of the normal anatomy. The exact degree of knee flexion should be taken into account for femoral tunnel placement and for describing tunnel positioning.

## Perspectives

The double bundle model of the ACL is a logical way to understand the three-dimensional ACL anatomy. Keeping the double bundle structure in mind facilitates a closer restoration of the original footprint anatomy, and improved biomechanics over traditional SBT approaches using the o'clock model. Another advantage of the anatomic double bundle concept is that it offers a model for description of different rupture patterns of the AM and PL bundle, which may guide surgical approach in isolated cases where only one bundle is torn. In these situations, it may be possible to preserve an intact bundle, and replace only the torn bundle. Finally, the concept may be applied to revision cases, specifically in patients where a PL bundle can be used to augment an SBT-reconstructed knee with adequate AP but poor rotational stability. Clinical outcomes studies are needed for an objective evaluation of the DBT approach. One important component in studying outcomes from DBT is inclusion of more accurate measurements of rotational stability and three-dimensional knee kinematics. Possible techniques include video motion analysis, computer navigation, RSA and dynamic MRI. In the future, these tools may help to determine the clinical utility of this approach to ACL reconstruction.

**Key words:** anterior cruciate ligament, anteromedial bundle, posterolateral bundle, anatomy, reconstruction.

## References

Amis AA, Dawkins GP. Functional anatomy of the anterior cruciate ligament. Fibre bundle actions related to ligament replacements and injuries. J Bone Jt Surg Br 1991: 73: 260–267.

Anderson AF, Dome DC, Gautam S, Awh MH, Rennirt GW. Correlation of anthropometric measurements, strength, anterior cruciate ligament size, and intercondylar notch characteristics to sex differences in anterior cruciate ligament tear rates. Am J Sports Med 2001a: 29: 58–66.

Anderson AF, Snyder RB, Lipscomb AB Jr. Anteriorcruciate ligament reconstruction. A prospective randomized study of three surgical

methods. Am J Sports Med 2001b: 29: 272–279.
Arnoczky SP. Anatomy of the anterior cruciate ligament. Clin Orthop Relat Res 1983: 172: 19–25.
Bach BR Jr, Tradonsky S, Bojchuk J, Levy ME, Bush-Joseph CA, Khan NH. Arthroscopically assisted anterior cruciate ligament reconstruction using patellar tendon autograft. Five to nine-year follow-up evaluation. Am J Sports Med 1998: 26: 20–29.
Bernard M, Hertel P, Hornung H, Cierpinski T. Femoral insertion of the ACL. Radiographic quadrant method. Am J Knee Surg 1997: 10: 14–22.
Brandsson S, Kartus J, Larsson J, Eriksson BI, Karlsson J. A comparison of results in middle-aged and young patients after anterior cruciate ligament reconstruction. Arthroscopy 2000: 16: 178–182.
Brandsson S, Karlsson J, Sward L, Kartus J, Eriksson BI, Karrholm J. Kinematics and laxity of the knee joint after anterior cruciate ligament reconstruction: pre- and postoperative radiostereometric studies. Am J Sports Med 2002: 30: 361–367.
Brown CH, Carson EW. Revision anterior cruciate ligament surgery. Clin Sports Med 1999: 18: 109–171.
Cha PS, Brucker PU, West RV, Zelle BA, Yagi M, Kurosaka M, Fu FH. Arthroscopic double-bundle anterior cruciate ligament reconstruction: an anatomic approach. Arthroscopy 2005: 21: 1275.
Dienst M, Burks RT, Reis PE. Anatomy and biomechanics of the anterior cruciate ligament. Orthop Clin North Am 2002: 33: 605–620.
Duthon VB, Barea C, Abrassart S, Fasel JH, Fritschy D, Menetrey J. Anatomy of the anterior cruciate ligament. Knee Surg Sports Traumatol Arthrosc 2005: 14: 204–213.
Eriksson K, Anderberg P, Hamberg P, Olerud P, Wredmark T. There are differences in early morbidity after ACL reconstruction when comparing patellar tendon and semitendinosus tendon graft. A prospective randomized study of 107 patients. Scand J Med Sci Sports 2001: 11: 170–177.
Gabriel MT, Wong EK, Woo SL, Yagi M, Debski RE. Distribution of *in situ* forces in the anterior cruciate ligament in response to rotatory loads. J Orthop Res 2004: 22: 85–89.
Gerich TG, Lattermann C, Fremerey RW, Zeichen J, Lobenhoffer HP. One- versus two-incision technique for anterior cruciate ligament reconstruction with patellar tendon graft. Results on early rehabilitation and stability. Knee Surg Sports Traumatol Arthrosc 1997: 5: 213–216.
Girgis FG, Marshall JL, Monajem A. The cruciate ligaments of the knee joint. Anatomical, functional and experimental analysis. Clin Orthop Relat Res 1975: 106: 216–231.
Giron F, Cuomo P, Aglietti P, Bull AM, Amis AA. Femoral attachment of the anterior cruciate ligament. Knee Surg Sports Traumatol Arthrosc 2005: 14: 250–256.
Goldblatt JP, Fitzsimmons SE, Balk E, Richmond JC. Reconstruction of the anterior cruciate ligament: meta-analysis of patellar tendon versus hamstring tendon autograft. Arthroscopy 2005: 21: 791–803.
Hara K, Kubo T, Suginoshita T, Shimizu C, Hirasawa Y. Reconstruction of the anterior cruciate ligament using a double bundle. Arthroscopy 2000: 16: 860–864.
Harner CD, Baek GH, Vogrin TM, Carlin GJ, Kashiwaguchi S, Woo SL. Quantitative analysis of human cruciate ligament insertions. Arthroscopy 1999: 15: 741–749.
Hollis JM, Takai S, Adams DJ, Horibe S, Woo SL. The effects of knee motion and external loading on the length of the anterior cruciate ligament (ACL): a kinematic study. J Biomech Eng 1991: 113: 208–214.
Kartus J, Movin T, Karlsson J. Donor-site morbidity and anterior knee problems after anterior cruciate ligament reconstruction using autografts. Arthroscopy 2001: 17: 971–980.
Kennedy JC, Weinberg HW, Wilson AS. The anatomy and function of the anterior cruciate ligament as determined by clinical and morhological studies. J Bone Jt Surg Am 1974: 56: 223–235.
Kummer B, Yamamoto M. Funktionelle Anatomie der Kreuzbaender. Arthroskopie 1988: 1: 2–10.
Loh JC, Fukuda Y, Tsuda E, Steadman RJ, Fu FH, Woo SL. Knee stability and graft function following anterior cruciate ligament reconstruction: comparison between 11 o'clock and 10 o'clock femoral tunnel placement. Arthroscopy 2003: 19: 297–304.
Muneta T, Sekiya I, Yagishita K, Ogiuchi T, Yamamoto H, Shinomiya K. Two-bundle reconstruction of the anterior cruciate ligament using semitendinosus tendon with endobuttons: operative technique and preliminary results. Arthroscopy 1999: 15: 618–624.
Musahl V, Plakseychuk A, VanScyoc A, Sasaki T, Debski RE, McMahon PJ, Fu FH. Varying femoral tunnels between the anatomical footprint and isometric positions: effects on kinematics of the anterior cruciate ligament-reconstructed knee. Am J Sports Med 2005: 33: 712–718.
Odensten M, Gillquist J. Functional anatomy of the anterior cruciate ligament and a rationale for reconstruction. J Bone Jt Surg Am 1985: 67: 257–262.
Petersen W, Tillmann B. Anatomy and function ofthe anterior cruciate ligament. Orthopaede 2002: 31: 710–718.
Sakane M, Fox RJ, Woo SL, Livesay GA, Li G, Fu FH. *In situ* forces in the anterior cruciate ligament and its bundles in response to anterior tibial loads. J Orthop Res 1997: 15: 285–293.
Sanchis-Alfonso V, Subias-Lopez A, Monteagudo-Castro C, Rosello-Sastre E. Healing of the patellar tendon donor defect created after central-third patellar tendon autograft harvest. A long-term histological evaluation in the lamb model. Knee Surg Sports Traumatol Arthrosc 1999: 7: 340–348.
Scopp JM, Jasper LE, Belkoff SM, Mooman CT III. The effect of oblique femoral tunnel placement on rotational constraint of the knee reconstructed using patellar tendon autografts. Arthroscopy 2004: 20: 294–299.
Shelbourne KD, Facibene WA, Hunt JJ. Radiographic and intraoperative notch width measurements in men and women with unilateral and bilateral anterior cruciate ligament tears. Knee Surg Sports Traumatol Arthrosc 1997: 5: 229–233.
Sommer C, Friederich NF, Muller W. Improperly placed anterior cruciate ligament grafts: correlation between radiological parameters and clinical results. Knee Surg Sports Traumatol Arthrosc 2000: 8: 207–213.
Souryal TO, Moore HA, Evans JP. Bilaterality in anterior cruciate ligament injuries: associated intercondylar notch stenosis. Am J Sports Med 1988: 16: 449–454.
Takahashi M, Doi M, Abe M, Suzuki D, Nagano A. Anatomical study of the femoral and tibial insertions of the anteromedial and posterolateral bundles of human anterior cruciate ligament. Am J Sports Med 2006; 34: 787–792.
Takai S, Woo SL, Livesay GA, Adams DJ, Fu FH. Determination of the *in situ* loads on the human anterior cruciateligament. J Orthop Res 1993: 11: 686–695.
Teitz CC, Lind BK, Sacks BM. Symmetry of the femoral notch width index. Am J Sports Med 1997: 25: 687–690.
Yasuda K, Kondo E, Ichiyama H, Kitamura N, Tanabe Y, Tohyama H, Minami A. Anatomic reconstruction of the anteromedial and posterolateral bundles of the anterior cruciate ligament using hamstring tendon grafts. Arthroscopy 2004: 20: 1015–1025.
Zaffagnini S, Martelli S, Acquaroli F. Computer investigation of ACL orientation during passive range of motion. 2004: 34: 153–163.